

Patient Name :	Gender : Male
Age : 65 Y	Date : Dec 01, 2024
Referring Doctor :	Patient ID :

OPG REPORT

FINDINGS:

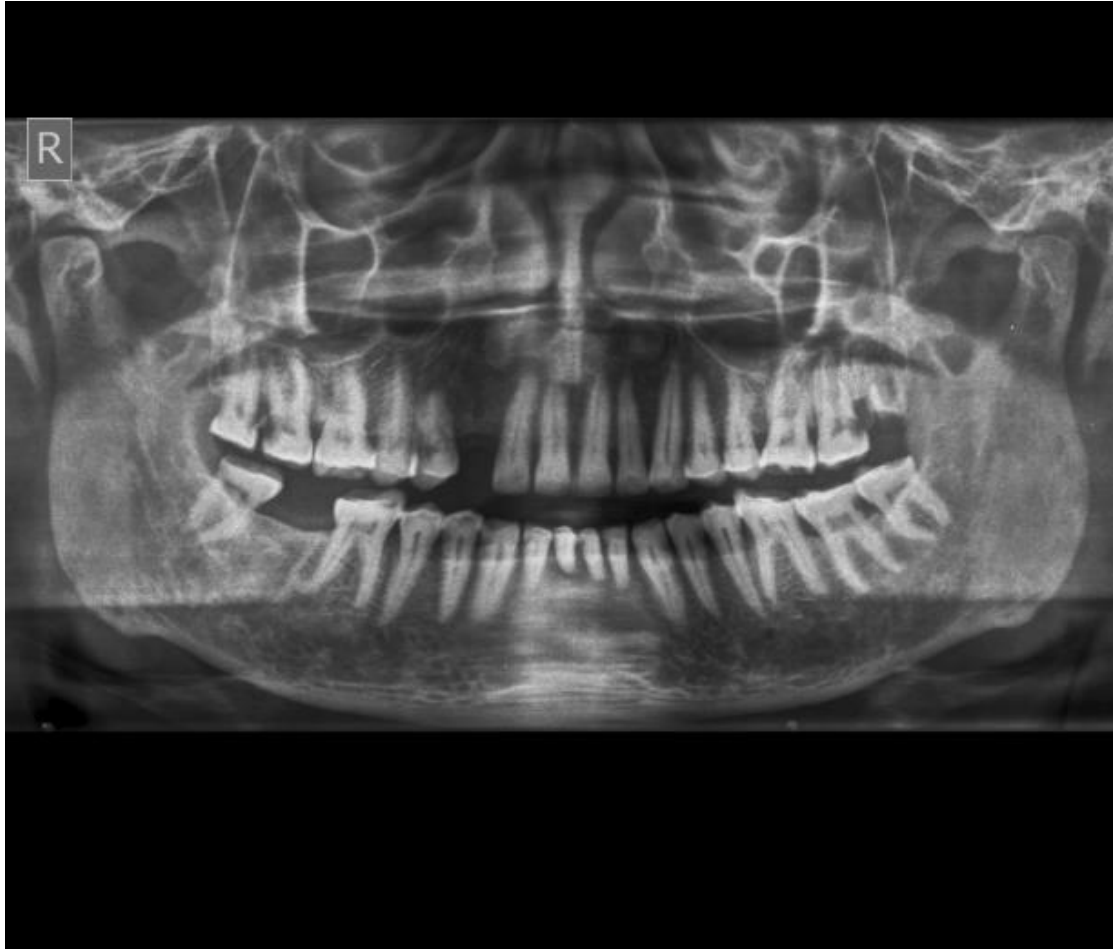
Severe attrition seen with 46 and 48
PDL widening with distal root of 46
Proximal caries seen with 17 and 18
Distal caries seen with 43
Distal caries seen with 14
Distal caries seen with 27
Root piece seen with 28
Root resorption seen with 41 with periapical abscess
Missing tooth with 13 and 47
Non healing socket seen 47

IMPRESSION:

Kindly co-relate with the clinical findings

Dr. (Name and Digital sign)
MDS (OM Radiology)
Reg - xxxxx

NOTE: This is an online interpretation of medical imaging based on clinical data, wherever available.
Not for Medicolegal purpose. In case of any discrepancy please reinvestigate the patient



NOTE: This is an online interpretation of medical imaging based on clinical data, wherever available. Not for Medicolegal purpose. In case of any discrepancy please reinvestigate the patient

Patient Name :	Gender : Female
Age : 32 Y	Date : Mar 13, 2024
Referring Doctor :	Patient ID :

OPG

FINDINGS:

Image Provided: Panoramic image with intact maxilla and mandible.

Diagnostic objectives: Pathology analysis

OPG reveals:

- Intact Maxilla & Mandible with normal Anatomy.
- Teeth missing - 25

*** 14,15,16:**

- Well defined radiopaque structures with radiodensity greater than enamel and dentin are noticed in the crown portions of teeth irt 14,15,16 s/o dental restorative materials.
- Multiple irregular radiolucencies are noticed in the crown portions of teeth just beneath the restorative materials irt 14,15,16 s/o recurrent caries.
- A linear radiopaque structures with radiodensity greater than enamel and dentin are noticed in the root canals of 16 s/o root canal filling materials like GP, indicates endodontically (RCT) treated irt 16.

*** 24:**

- A irregular radiolucency is noticed in the crown portions of 24 s/o dental caries.
- A ill-defined periapical radiolucency with loss of lamina dura is noticed irt 24 s/o periapical abscess.

***Other findings :**

- Edentulous spaced is noticed distal to 24 and mesial to 26 s/o missing 25.

NOTE: This is an online interpretation of medical imaging based on clinical data, wherever available. Not for Medicolegal purpose. In case of any discrepancy please reinvestigate the patient

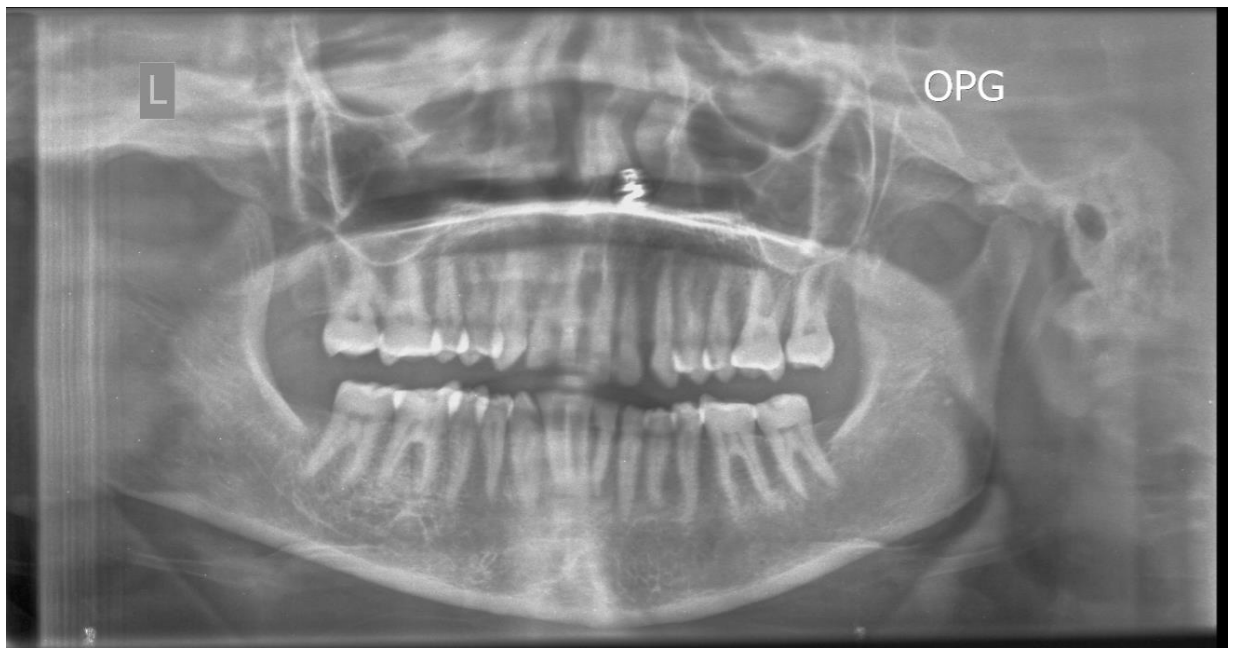IMPRESSION:

*** Radiographic Diagnosis:**

- Recurrent dental caries irt 14,15,16.
- Endodontically (RCT) treated irt 16.
- Dental caries with periapical abscess irt 24.
- Edentulous irt 25.

****Clinical evaluation and correlation is recommended.***

**Dr (Name and Digital Sign)
MDS OM RADIOLOGY
Reg - xxxx**



NOTE: This is an online interpretation of medical imaging based on clinical data, wherever available. Not for Medicolegal purpose. In case of any discrepancy please reinvestigate the patient